

# Blood changes with chronic illness and a theory about total and partial wound units

By Dr. Erik O.H. Enby, MD  
© Erik Enby, Göteborg, 1997-2002

## Blood changes with chronic illness and a theory about total and partial wound units

All rights reserved. No part of this article may be reproduced or transmitted in any form or by any means, electronic or mechanical, including photocopying, recording or any information storage and retrieval system, without permission in writing from the publisher. Illustrations: Lisa Örtengren.

Erik Enby • Nordisk Medicinkonsult AB • Karl Johansgatan 49B • SE-414 55 Göteborg, Sweden  
Phone: +46-31-14 24 14 • Fax: +46-31-14 06 32 • E-mail: erik@enby.se • Internet address: www.enby.se

---

## Abstract

Dr. Erik Enby has in the blood from chronically ill individuals observed large amounts of unknown particles. The particles seem to be able to invade the red blood cells and then these generally show a strong tendency to get stuck to each other. The particles are also involved in the construction of special structures that are often visible in the blood and might cause somatic destruction on various levels.

## Purpose

Description of particles in blood from subjectively healthy people and in connection with these particles structures growing in blood from chronically ill people, and the presentation of a theory that explains a change – or deterioration principle in the soma.

## Method

Vital blood from thousands of chronically ill people belonging to an average Swedish disease panorama has been studied in microscope, with ordinary lightfield and with the Nomarski's interference contrast and it has been compared with vital blood from approximately 200 subjectively healthy individuals.

## Result

Small oscillating 0,5 – 1-micrometer big particles were a common finding in the blood from subjectively healthy people. In the blood from chronically ill people, very often more, bigger and variously shaped particles were found, that sometimes seemed to invade the red blood cells. The particles also appeared in abundant amounts together with a special structure principle that appeared in different sizes among the blood cells.

## Conclusion

Dr. Erik Enby suspects that some of the particles may cause formation and growth of freely floating structures in the blood from chronically ill individuals. The growth of these structures is assumed also to take place in solid parts of the soma and thus cause local destruction that either increase or heal with scars that will lead to either stationary reduced or gradually decreased degree of efficiency of the soma.

## Introduction

Darkfield microscoping of blood reveals that the blood in addition to red and white blood cells contains large amounts of oscillating, very tiny particles.

In the blood of chronically ill people several bigger particles, sometimes of various shapes, occur. Many researchers have assumed that these particles constitute some kind of microbial growth and considered them as a possible cause of the development of chronic disease conditions.<sup>1 2</sup> However, the proof of this was never submitted to any analysis.

In order to find out the possible role of the particles in the development of chronic disease conditions in general, the following microscopic analysis was performed.

An ordinary lightfield microscoping 100 times enlarged was used to get a first, quick orientation of the blood sample, and locally a more special microscoping of this was carried out in co-operation with the “Nomarski’s interference contrast method”.

## Material and methods

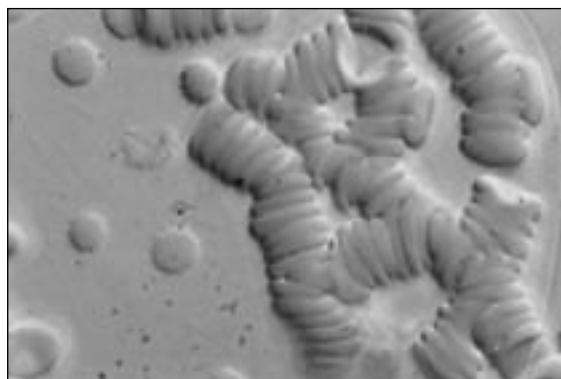
The drop of blood was obtained from the fingertip. In order to avoid any disturbance of the blood as far as possible, strong antiseptics were avoided and the blood immediately could flow out into a thin film between sterilized cover – and object glasses. The surface of the blood film has an average of 13 cm<sup>2</sup> and the microscoping was performed immediately after the test.

## Microscoping equipment


Leitz’ laboratory microscope Dialux 20, equipped with a 100W halogen lamp. Modified UK condenser for darkfield, lightfield, phase contrast and interference contrast. Plan-Fluotar objective. Binocular photo tube FSA. All documentation has been compiled with Leitz’ fully automatic microscope camera Vario-Orthomat.

## Results

The blood cells in the blood from chronically ill people, different from those of subjectively healthy people, in almost 100% of the cases tended to get stuck to each other, and sometimes there were no freely floating blood cells in the plasma (*Figure 1*).



*Figure 1. Interference contrast 1.200 times enlarged. Agglutinated red blood cells. Single, devitalized, free red blood cells. Small particles visible in the plasma and among, on or in the red blood cells.*



*Figure 2. Interference contrast 1.200 times enlarged. The conglomeration of particles lying among the red blood cells, that are extremely changed.*

Small spherical irregularly oscillating particles of the size of up to one micrometer in diameter were often observed in the blood plasma from subjectively healthy people. In the blood from chronically ill people more and bigger particles often appeared. They appeared single but also in small colonies in the plasma (Figure 2). Further they also seemed apt to be transformed into small, longish forms, that appeared in both plasma and the red blood cells that then usually were extremely changed in shape (Illustration 2)<sup>3</sup>. In separate cases about 100% of the red blood cells appeared in a thorn-apple form.

Round disc-shaped regions in the blood films were often observed (Figure 3). Sometimes up to 5 of those appeared on an object glass (Illustration 1). The size of those varied up to 300 micrometer in diameter. The inner part (nucleus) of a region like that was darker than its periphery (corona zone) and clearly demarcated against it (Illustration 1, 2 and figure 3)<sup>4</sup>.

Interference contrast microscoping 1200 times enlarged, showed that the darker inner part could be compared with an absolutely sterile moon landscape, while the lighter periphery consisted of lots of oscillating particles varying in shape, similar to those that could be seen in the remaining blood. In some cases the occurrence of these discoveries fluctuated from time to time and sometimes some chronically ill people pervadingly showed a completely normal blood morphology.




Figure 3. Interference contrast 1.200 times enlarged. Disc-formed region in the blood film. Red blood cells powerfully agglutinated.

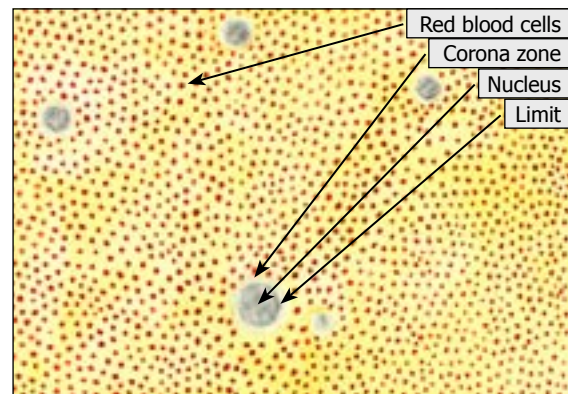


Illustration 1. 100 times enlarged. A lot of disc-formed regions among the red blood cells.

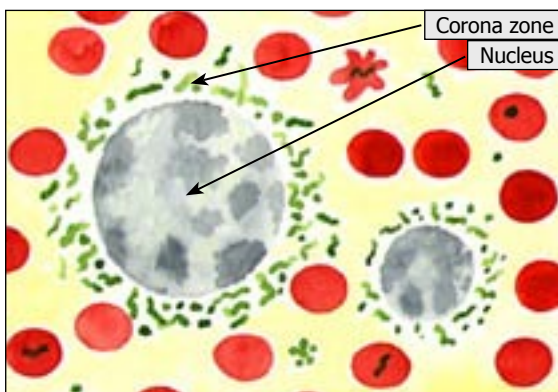


Illustration 2. 1.200 times enlarged. Two disc-formed regions in the blood film. Separate diversified particles in plasma and blood cells, sometimes showing form-changes and lots of pleomorphic structures in the corona zone.

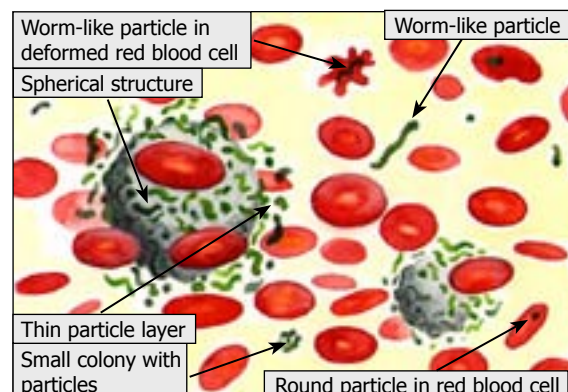


Illustration 3. 1.200 times enlarged. The disc-formed regions are assumed to exist in the blood as spherical structures with particle front to surrounding blood. The particles occur in colonies or separate in the blood cells and show different forms.

## Discussion

At the beginning of the examination there were three conditions in the blood from chronically ill people that surprised.

- a) The often most abundant numbers of oscillating particles of different sizes and shapes occurred not only in the blood plasma, but also seemed apt to invade the red blood cells.
- b) The often most abundant numbers of deformed and apparently destroyed blood cells.
- c) The blood cells often tended to get stuck to each other. The question arose if the deformation of and the agglutination tendency among them were caused by the large amount of oscillating particles and thus should be expected to occur already in the soma or if external influence would be the reason therefore.

As the deformation of blood cells all the way into thorn-apple forms sometimes could be almost 100% and the agglutination tendency so strong that no free blood cells existed in the plasma and never did so in the blood from subjectively healthy people, this was taken as a grant that deformation and agglutination already existed in the soma, and the suspicion that these phenomena only were artefacts, was reduced.

Since the agglutination occurs even in other body fluids, for example when lactic acid bacteria sour the milk, by analogy therewith a powerful lumping of the red blood cells could be an infection symptom. Thus, the agglutination tendency of the red blood cells in the blood from chronically ill people may indicate a spread microbial growth in the body fluids by analogy with an infection.

This made one look upon the often occurring large amount of particles in the blood plasma and blood cells in the blood from chronically ill people as microorganisms. Might it be that sometimes these may also attack the blood cells and thus change their form and that the agglutination tendency came into existence because a microbial growth existed in the blood?<sup>5</sup>

Consequently it is noticeable that these three conditions often occurred in the blood of chronically ill people and therefore this was taken as a proof for an ongoing development of a disturbance in the soma. Since also blood from subjectively healthy people occasionally changed in a similar way the question arose, would this indicate a beginning somatic disturbance when the individual was still in the so-called period of incubation. So far the microscoping had only given a hint of all this. It was mostly the vertical source of knowledge, that is the intuition, in co-operation with my own experience, that had to be the guide in order to decide if a blood picture seemed to be disturbed or not<sup>6</sup>.

As agglutination tendency and deformed blood cells hardly existed with subjectively healthy people, it was supposed that the blood from a chronically ill person, due to increased viscosity and the often large amount of bad blood cells, probably serves its functions in the soma with a lower degree of efficiency than is the case with subjectively healthy people, whose blood cells were lying freely and had a normal look.

Not until it became apparent that the particles sometimes formed conglomerations in the blood plasma and existed in large amounts in the corona zones of the disc-shaped regions, it seemed possible to get an idea of their importance on a more rational level. It couldn't be wrong to consider these regions a result of a flattening of spherical structures floating among the blood cells in the drop of blood that floated out between the object – and cover glasses and thus formed a transparent, thin blood film. Further, you could imagine that these structures are limited against surrounding blood by a layer consisting of the particles visible in the corona zones (*Illustration 3*).

Since these postulated spherical structures must have been formed and the regions have different sizes, it was assumed that they grow and that the peripheral particle layer makes the growth zone. The increasing size of the structures would later on mean that the capillary net will catch them, which would be the reason why they are often found in drops of blood from for example the fingertip.

These floating, postulating structures among the blood cells that for easily explained

reasons still haven't been observed in their natural state, of course, do exist and they will now be the base for the continued discussion. This will deal with the possibility that solid tissues may form substratum for this type of growing structures with a particle front to the surroundings (*Illustration 4, 5*). On the spot for the growth of structure, tissue destruction then would take place and sometimes a perforation of the organ surface with outwards emptying of the structure contents will take place (*Illustration 6*). This is generally called pus and is then accordingly to this theory equivalent to the darker part, nucleus, in a disc-shaped region.

The defect that occurred on the organ surface can be classified as a wound and since the postulating growing structures actually can lead to tissue destruction and wound, hereafter they will be called wound units.

A wound unit in a solid tissue would before perforation outwards be the total so-called internal wound, the spherical wound surface bordering the surrounding tissue holds the wound contents. At perforation the total internal wound is changed into a partially external wound, whose bowl-shaped wound surface will be covered with rests from the structure contents and in size be equivalent to only part of the theoretically totally possible wound surface. In both cases, of course, there is a particle front or growth zone to an adjacent tissue (*Illustration 7*).

The cells that have made room for inner and outer wound formations in the blood may have their equivalence in the devitalized blood cells changed in shape, which so often occur in

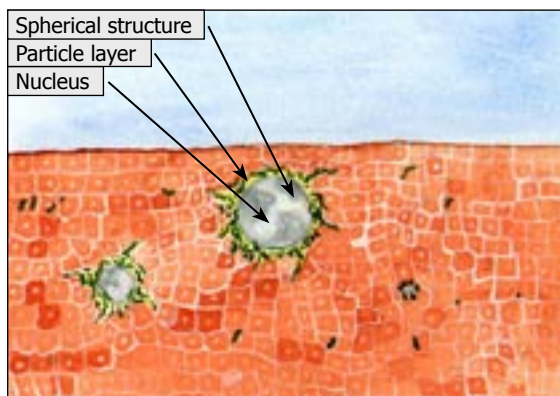


Illustration 4. 1.200 times enlarged. Spherical structures in solid tissue with particle front to their surrounding and separate variously formed particles spread in it.

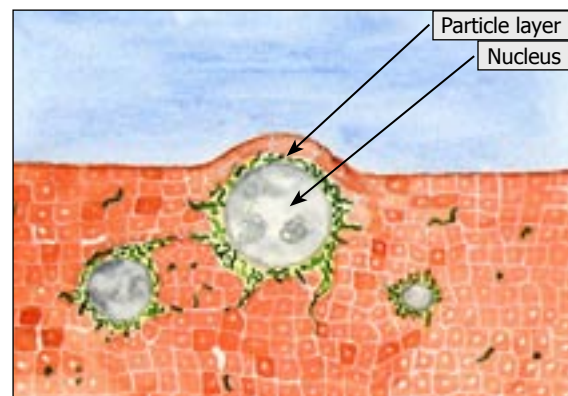


Illustration 5. 1.200 times enlarged. Spherical structures in solid tissue. The one in the middle has increased in size. That is why it bends over the organ surface.

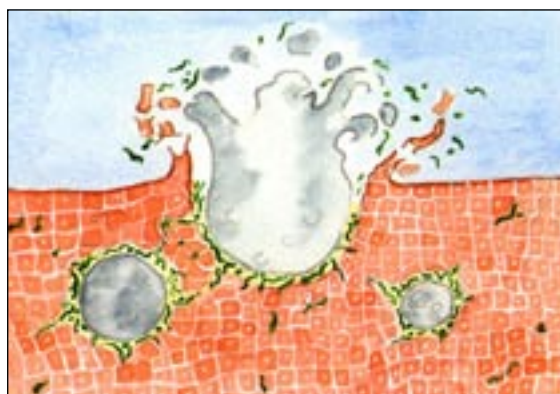


Illustration 6. 1.200 times enlarged. A structure, that breaks through the surface of the organ and empties its contents.

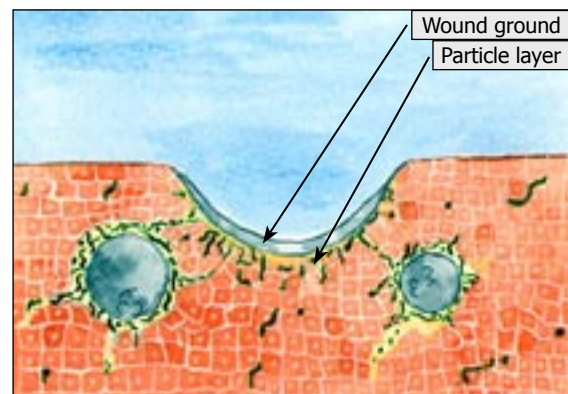


Illustration 7. 1.200 times enlarged. Defect in the organ surface after emptying the contents of the structure. The crescent shaped cross section through the bowl shaped rest of the contents of the structure (nucleus), now forms a wound ground, under which the particle front against surrounding tissue is situated.

connection with chronic disease.

Wound units might lead to tissue destruction in any part of the soma. The local tissue losses certainly in most cases are replaced by a stationary scar tissue, but sometimes this might not occur. In the latter case, the wound stays open and if the particle front against surrounding tissue stays active, it can also increase in size. As something in between, an increasingly widespread scar formation may be a possibility if the scar tissue is formed directly on the track of the particle front. The different alternatives will lead to either a stationary reduced or in various respects a gradual decrease of efficiency with the soma.

The fact is that blood from chronically ill people can be completely free from the above-mentioned findings and look perfectly normal. This may indicate an inherent ability on the particles to be drawn to and stay in other areas of the soma.

The fact that they seem to be able to transform into small, longish forms may mean that they also change characteristics and look for other environments than the one offered by the blood. Another possibility is that they have been buried among agglutinated red blood cells, meaning that they are taking part in the agglutination. This might be some explanations of the blood sometimes being completely free from the above described findings, even if a severe chronic disease exists.

## Epilogue

In the plasma among the blood cells in the blood from chronically ill people, lots of variously formed particles exist. They can exist separately or form colonies and they can also invade the red blood cells. Probably several different types of particles exist. A common characteristic of these is that they all seem to be involved in the growing process of architecturally similar structures, some of which are probably able to grow in solid tissues as well.

In accordance with a dominating growth process changing and finally "impoverishing" a ground, one may believe that such processes in the soma slowly devastate it and in that way different disease conditions may be realized. A first knowledge of such growing processes can be gained by blood microscoping.

## References

<sup>1</sup> Béchamp Antoine

(1911). *The blood and its third anatomical element*. Philadelphia. Boericke & Tafel.

<sup>2</sup> Enderlein, Günther

(1981). *Bakterien-Cyclogenie*. (2. Ausgabe). Hoya. Semmelweis-Verlag.

<sup>3</sup> Enby Erik O. H.

(1989). *Die Präsenz zyklischer mikrobischer Prozesse Nachgewiesen im Blut von chronisch erkrankten Patienten. (The presence of cyclical microbial processes indicated in the blood of patients with chronic diseases)*. Hoya. Semmelweis-Verlag.

<sup>4</sup> Enby, Erik O. H.

(1984). *Mikrobliknande bildningar i blod vid kroniska sjukdomar. (Microbe-like formations in the blood of chronically diseased individuals)*. Svensk Tidskrift för Biologisk Medicin, Swedish Journal of Biological Medicine. No 1. p 22-26.



---

<sup>5</sup>Scholander C., Treutiger, C.J., Hultenby, K. & Wahlgren, M.  
(1996). *Novel fibrillar structure confers adhesive property to malaria-infected erythrocytes*. Nature Medicine.  
Nr 2. s 204-208.

<sup>6</sup>Johannes Paulus II  
(1992). *Vetenskapens världsbild och tron*. Signum. Volume 18. No 9/10. p 301-304.